

# Facial nerve paralysis: A complication of acute mastoiditis.

A. Thangaroopan, BSc<sup>1</sup>, MM Carr, DDS, MD<sup>2</sup>, EAS Massoud, MB, MSC, FRCSC<sup>2</sup>

<sup>1</sup>Med II, Faculty of Medicine, Dalhousie University, <sup>2</sup>Department of Otolaryngology, Dalhousie University, Halifax, N.S., B3H 4H7

A 64 year-old male was admitted with a five-day history of left otalgia accompanied by vertigo and a progressive left-sided facial paresis. Prior to admission he had been treated with oral antibiotics with no significant improvement. He was a known diabetic treated with Chlorpromamide. Past medical history was remarkable for poor visual acuity attributable to diabetic retinopathy and long-standing left-sided hearing loss.

On examination, the patient was afebrile but appeared to be in moderate distress. He had tenderness and erythema over the mastoid process and an obvious left facial droop graded IV/VI (Table 1- House-Brackmann scale). Bell's phenomenon, where the eye-balls roll upward with attempted eye closure, was normal. A conductive hearing loss was present in the left ear as determined by the Weber and Rinne tests. Otosopic examination revealed debris and some granulation tissue at the base of the external auditory canal (EAC). The tympanic membrane (TM) was pulsatile anteriorly but immobile on insufflation. There was no edema or erythema of the EAC or TM. No cervical adenopathy, dysphagia, or dysphonia was present. Nystagmus was absent. Neurological exam was significant for diminished peripheral sensation and an unsteady gait. The rest of the physical exam was within

normal limits.

## INVESTIGATIONS

Routine blood investigations were essentially normal. Urinalysis showed moderate glycosuria and serum glucose of 28 mmol/L. The patient was admitted with a provisional diagnosis of malignant otitis externa and treatment was initiated with a regimen of Ciprofloxacin 400 mg IV q12h and topical instillation of Gentamicin-Betamethasone otic solution. A thin section computed tomography (Figure 1) of the left temporal bone showed opacification of the left mastoid air cells and soft tissue obliteration of air spaces in the middle ear cleft, mastoid antrum and mastoid air cell system. There was no evidence of loss of bony septation in the mastoid and no other intracranial and infratemporal complications were identified (Table 2).

**Table 2: Complications of otitis media(1).**

Infratemporal	Intracranial
serous otitis	meningitis
tympanosclerosis	lateral sinus thrombosis
perforation	otitic hydrocephalus
otorrhea	extradural abscess
mastoiditis/petrositis	subduralabscess
subperiosteal abscess	brain abscess
facial nerve palsy	
labyrinthitis	
temporomandibular joint dysfunction	
osteomyelitis	

**Table 1: House-Brackmann Grading of Facial Paralysis (7).**

Grade	Description	Features
I	Normal	Normal facial function
II	Mild dysfunction	Slight asymmetry of facial movement
III	Moderate dysfunction	Obvious asymmetry, some movement
IV	Moderate-severe weakness	Obvious asymmetry, no forehead movement
V	Severe dysfunction	Only barely perceptible motion
VI	Total paralysis	No movement

The diagnosis of acute otitis media with mastoiditis was made and the patient underwent a myringotomy and Teflon tube insertion for drainage of the serous otitis media. A specimen of the middle ear effusion was collected for culture and Gram stain, but there was no bacterial growth noted.

On Day 2, he complained of persisting otalgia and retroauricular tenderness. A technetium bone scan showed a focus of increased uptake in the left mastoid region. There was no evidence of extension to the adjacent osseous structures, petrous apex, or floor of the middle cranial fossa. This was consistent with a diagnosis of acute mastoiditis. Antibiotic treatment was thus changed to Cefuroxime 750 mg IV q8h to provide better

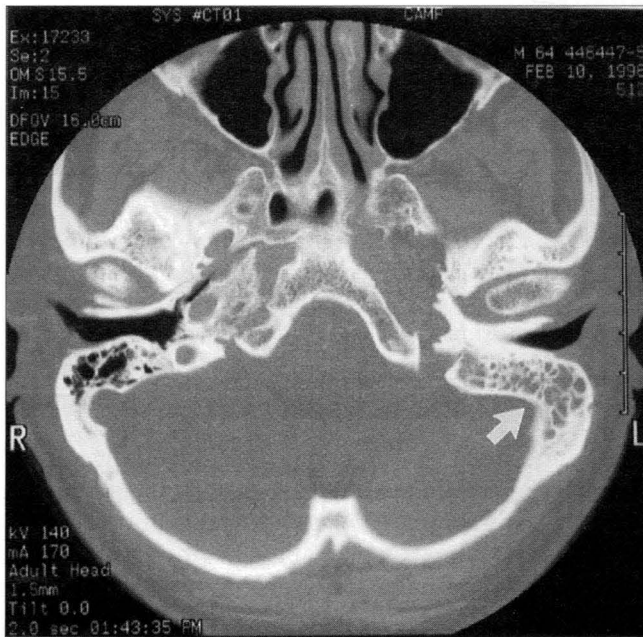


Figure 1a

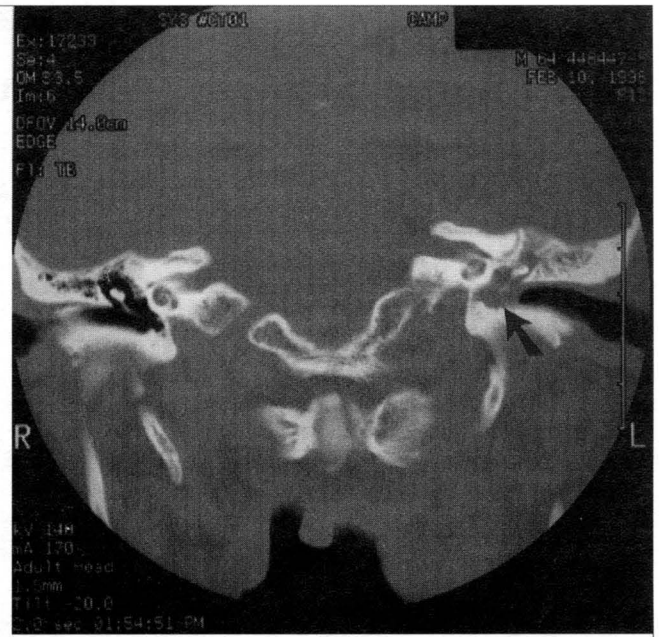


Figure 1b

**Figure 1:** Figure 1a is an axial view and figure 1b is a coronal view through this patient's temporal bone region with thin section computer tomography. On 1a, the left mastoid air cells are opacified (arrow) as compared to those on the right. On 1b, the left middle ear cavity is opacified also (arrow). This suggests fluid or soft tissue filling this normally air-filled cavity. The white object in the middle ear cavity is the malleus. The snail shell-shaped structure medial to the middle ear is the cochlea. The head appears to be asymmetrical because of patient positioning.

coverage of respiratory pathogens common in this disease.

Two days later, the patient developed a left mandibular molar toothache requiring tooth extraction. The rest of the clinical course was characterized by slow improvement of facial function to grade III/VI, and decreased otorrhea, eventually resolving after 9 days of treatment. His vertigo and periauricular tenderness gradually improved over this time period. He was discharged home with a prescription for a 10 day course of Cefuroxime axetil.

On reassessment one week later, he complained of left aural fullness and facial nerve function remained unchanged. At one month, his facial paresis had improved to grade I/VI and his ear was clear.

## DISCUSSION

Acute mastoiditis is an inflammatory disease of the mucosa lining the mastoid air cell system (1). Continued otorrhea, mastoid tenderness, temporal headache and postauricular swelling with downward displacement of the pinna, are indications of mastoiditis. CT scans of the temporal bone are diagnostic, showing opacification in the region of the mastoid system (1).

Acute mastoiditis is nearly always preceded by an acute suppurative otitis media (AOM) (2). when suppurative effusion is present behind the tympanic membrane pneumatic otoscopy greatly improves the diagnostic acumen, since fluid behind the drum is revealed by fluctuating air-fluid levels or immobility of

the drum (1). The middle ear cleft and mastoid air cell system communicate via a small opening, the aditus ad antrum, which allows aeration of the mastoid sinus. Transmission of infection occurs by contiguity of the mucosal lining of these two regions of pneumatization (1). Thus the causative organisms of AOM (*Streptococcus pneumoniae*, *Hemophilus influenza*, *Moraxella catarrhalis* and *Staphylococcus aureus*) are the same pathogens that cause acute mastoiditis (1).

Treatment consists of antibiotic therapy and establishment of adequate drainage (2). Current management standards consist of high potency parenteral antibiotics and topical antibiotic-steroid solutions. Antibiotic therapy is guided by culture, but broad spectrum antibiotics with adequate staphylococcal coverage should be instituted while awaiting results (2). Currently recommended first line defense regimens include: Amoxicillin clavulanate, Erythromycin, Azithromycin or Clarithromycin (3).

Surgical treatment with simple mastoidectomy is required when there is bone destruction, lack of resolution with antibiotic treatment, or complications (1). Mastoidectomy involves opening and debriding the mastoid air cells through an opening in the cortical bone overlying them. Since the advent of antibiotics, the natural history of otitis media and mastoiditis has radically changed. CNS complications of infectious middle ear disease that were once common are now rare (4). Persistence of infection and inadequate antibiotic therapy predisposes to the development of sequelae including meningitis, facial paralysis, labyrinthitis, lateral sinus

and sigmoid sinus thrombophlebitis, osteomyelitis and abscess formation (subperiosteal, epidural, subdural, and brain abscess) (4). Intracranial complications develop by direct extension of the infectious process through bone (osteitis), hematogenous dissemination or by preformed pathways including the labyrinthine and endolymphatic channels (4).

Meningitis is a potentially fatal complication of mastoiditis and should be suspected in patients with decreasing mental status, fever, meningeal signs and a recent exacerbation of ear disease or drainage. Lumbar puncture is the preferred diagnostic test (1).

Lateral sinus thrombophlebitis can be related to the presence of bone-eroding granulation tissue in acute coalescent mastoid, initiating a cascade of events leading to inflammation and formation of an intraluminal thrombus (5). Fulminant septic emboli have been reported in rare cases (5).

Facial nerve palsy in a patient with suppurative otitis media or mastoiditis reflects the anatomical relationship between the middle ear cavity and CN VII. In the acute setting it results from inflammation of the nerve in its middle ear segment through a dehiscence in the bony fallopian canal (1). The most common pattern of dehiscence is in the region of the oval window which abuts the footplate of the stapes (6). Thus suppurative effusion in the middle ear or mastoid sinus can affect the function of the facial nerve en route, perhaps mediated by bacterial toxins. The occurrence of vestibular symptoms such as vertigo, as in this patient, suggests concomitant labyrinthitis owing to the proximity of the semicircular canals to the mastoid air cells.

Diabetics have impaired immunological status and can present with uncommon or severe infections. This elderly diabetic male presented with an acute otitis media with mastoiditis, an unusual condition for adults. He had vertigo likely related to toxic labyrinthitis and ipsilateral facial paresis. This constellation of clinical findings reflects the anatomical proximity of the affected structures in the temporal bone.

## REFERENCES

1. Neely JG. Complications of temporal bone infection. In Cummings CW, Frederickson JM, Harker LA, Krause CJ, Schuller DE (Eds.). *Otolaryngology-head and neck surgery*, 2nd edition. Mosby Year Book, St Louis, 1993;2894-2847.
2. Luntz M, Keren G, Nusem S, Kronberg J. Acute Mastoiditis-revisited. *ENT Journal*, 1994;73(9):648-654.
3. Sanford JP, Gilbert DN, Gerding JL, Sande MA. Guide to antimicrobial therapy. Antimicrobial Therapy Inc, Dallas TX, 1994.
4. Gower D., Intracranial complications of acute and chronic infectious ear disease: A problem still with us. *Laryngoscope* 1983;93:1028-1033/
5. Leiberman A, Lupu L, Landsberg R, Fliiss DM. Unusual complications of otitis media. *American Journal of Otolaryngology* 1994;15(6):444-448.
6. Spector JG, Xianxi G. Ossification patterns of the tympanic facial canal in the human fetus and neonate. *Laryngoscope* 1993;103(9):1052-1065.
7. House JW, Brackmann DE. Facial nerve grading systems. *Laryngoscope* 1983;93:1056-1069.



# University Videoconferencing Services

*"changing the way we learn and do business"*

Videoconferencing is now a practical reality for almost any business or educational institution. Given the state of the art advances in performance, economical pricing, integration of essential tools, and links to worldwide telephone networks--more and more organizations are discovering the competitive advantages and power of videoconferencing.

Today, with every aspect of business and education becoming increasingly global, videoconferencing provides the means for groups and individuals to share information spontaneously, compressing both time and distance. Whether they are separated by a few kilometers or several thousand, videoconferencing offers today's leaders a way to break new ground worldwide.

Put University Videoconferencing Services to work for you today:

We offer:

- ◆ full technical support
- ◆ travel avoidance
- ◆ reduced expenses
- ◆ instant visual communication
- ◆ powerful visual presentations
- ◆ transmission of x-rays, slides, videotapes, computerized images, documents, and scans



Perfect for:

- ◆ conferences
- ◆ interviews
- ◆ meetings
- ◆ distance learning/training

for further information or to book the videoconferencing facility, please contact us.

A joint initiative of  
**Medical Computing & Media Services** and  
**Continuing Medical Education**  
Sir Charles Tupper Building  
Dalhousie University  
5859 University Avenue  
Halifax, Nova Scotia, Canada B3H 4H7  
fax: (902) 494-2046  
Phone: (902) 494-2867  
e-mail: videocon@Dal.ca

on the internet: <http://image.med.dal.ca/mcmsfac7.shtml>