


Canadian Association of Radiologists Thoracic Imaging Referral Guideline

Candyce Hamel¹ , Barb Avard², Catherine Belanger³, Patrick Bourgoïn⁴, Stephen Lam⁵, Daria Manos⁶, Alan Michaud⁷, Brian H. Rowe⁸, Kevin Sanders², and Ana-Maria Bilawich⁹

Canadian Association of Radiologists Journal
1–8

© The Author(s) 2023



Article reuse guidelines:
sagepub.com/journals-permissions
DOI: 10.1177/08465371231214699
journals.sagepub.com/home/caj



Abstract

The Canadian Association of Radiologists (CAR) Thoracic Expert Panel consists of radiologists, respirologists, emergency and family physicians, a patient advisor, and an epidemiologist/guideline methodologist. After developing a list of 24 clinical/diagnostic scenarios, a rapid scoping review was undertaken to identify systematically produced referral guidelines that provide recommendations for one or more of these clinical/diagnostic scenarios. Recommendations from 30 guidelines and contextualization criteria in the Grading of Recommendations, Assessment, Development, and Evaluations (GRADE) for guidelines framework were used to develop 48 recommendation statements across the 24 scenarios. This guideline presents the methods of development and the referral recommendations for screening/asymptomatic individuals, non-specific chest pain, hospital admission for non-thoracic conditions, long-term care admission, routine pre-operative imaging, post-interventional chest procedure, upper respiratory tract infection, acute exacerbation of asthma, acute exacerbation of chronic obstructive pulmonary disease, suspect pneumonia, pneumonia follow-up, immunosuppressed patient with respiratory symptoms/febrile neutropenia, chronic cough, suspected pneumothorax (non-traumatic), clinically suspected pleural effusion, hemoptysis, chronic dyspnea of non-cardiovascular origin, suspected interstitial lung disease, incidental lung nodule, suspected mediastinal lesion, suspected mediastinal lymphadenopathy, and elevated diaphragm on chest radiograph.

Keywords

thoracic, lung, chest, diagnostic imaging, referrals, guideline

Introduction

Beginning in November 2022, an Expert Panel (EP) comprised of radiologists, respirologists, emergency and family physicians, a patient advisor, and an epidemiologist/guideline methodologist met to develop a new set of recommendations specific to referral pathways for conditions related to the thorax, including asymptomatic individuals, symptomatic patients, and other scenarios requiring imaging of the thorax. Through discussion (via a virtual meeting) followed by offline communication, the EP developed a list of 24 clinical/diagnostic scenarios to be covered by this guideline. These recommendations are intended primarily for referring clinicians (eg, family physicians, specialty physicians, nurse practitioners); however, they may also be used by radiologists, individuals/patients, and patient representatives.

Our methods describing the guideline development process, including the rapid scoping review to identify the evidence base, has been published in *CMAJ Open*¹ and an editorial to this series of guideline publications is available in *CARJ*.² The application of well-established scoping review and rapid review guidance (JBI,³ Cochrane Handbook,⁴ Cochrane Rapid

Review Methods Group⁵) and guideline methodology (ie, Grading of Recommendations Assessment, Development, and Evaluation or GRADE^{6,7}) were used to identify the evidence-base and to guide the Expert Panel in determining the strength and direction of the recommendations for each clinical scenario

¹ Canadian Association of Radiologists, Ottawa, ON, Canada

² North York General Hospital, Toronto, ON, Canada

³ Ormstown Medical Clinic, Ormstown, QC, Canada

⁴ Centre hospitalier de l'Université de Montréal, Montréal, QC, Canada

⁵ BC Cancer Research Institute, Vancouver, BC, Canada

⁶ QEII Health Sciences Centre, Victoria General Hospital, Halifax, NS, Canada

⁷ University of Waterloo, Waterloo, ON, Canada

⁸ Department of Emergency Medicine, University of Alberta, Edmonton, AB, Canada

⁹ Gordon and Leslie Diamond Health Care Centre, University of British Columbia, Vancouver, BC, Canada

Corresponding Author:

Ana-Maria Bilawich, Gordon and Leslie Diamond Health Care Centre, University of British Columbia, 2775 Laurel Street, Vancouver, BC V5Z 1M9, Canada.

Email: anamaria.bilawich@vch.ca

Table 1. Recommendation Text, Symbol, and Interpretation.

Recommendation	AGAINST	FOR
STRONG	<p>Strong, against “we recommend against” (⇓)</p> <ul style="list-style-type: none"> All or almost all informed people would not recommend/choose the course of action and only a small proportion would. 	<p>Strong, for “we recommend” (⇑)</p> <ul style="list-style-type: none"> All or almost all informed people would recommend/choose the course of action and only a small proportion would not. Request discussion if the intervention is not offered.
CONDITIONAL	<p>Conditional, against “we suggest against” (⇓)</p> <ul style="list-style-type: none"> Most informed people would not recommend/choose the course of action, but a substantial number would. This may be conditional upon patient values and preferences, the resources available or the setting in which the intervention will be implemented. 	<p>Conditional, for “we suggest” (⇑)</p> <ul style="list-style-type: none"> Most informed people would recommend/choose the course of action, but a substantial number would not. This may be conditional upon patient values and preferences, the resources available or the setting in which the intervention will be implemented.

Note: Down arrows are red and Up arrows are green when available in colour.

Created using the guidance provided in Andrews and colleagues.⁶

(Table 1). The quality of conduct and reporting of the included guidelines identified in the scoping review were evaluated with the AGREE-II checklist,⁸ using a modified scoring system. In instances where guidelines were lacking, expert consensus was used to develop the recommendation. Contextualization to the Canadian health care system was considered for each recommendation, with discussion around the factors found in the Evidence to Decision framework in GRADE for guidelines (eg, balance of desirable and undesirable outcomes, values and preferences, resources implications).⁷

A systematic search for guidelines (with an a priori defined inclusion criteria) was run in Medline and Embase on January 5, 2023. The search was limited to publications from 2017 onward (Supplemental Appendix 1). Supplemental searching included the following national radiology and/or guideline groups: the American College of Radiology, the National Institute for Health and Care Excellence, and the Royal College of Radiologists 8th Edition (2017). Recommendations for each clinical scenario were formulated over 2 virtual meetings in April 2023. External review and feedback were obtained from radiologists, emergency and family physicians, and a nurse practitioner. The full guideline can be found on the CAR website (www.car.ca).

Results

Systematic Scoping Review

A total of 8479 records were identified through the electronic database and 7 additional records were added from the supplemental search. Thirty guidelines, plus 2 companion papers, were included (Figure 1). Potentially relevant guidelines published in languages other than English can be found in Supplemental Appendix 2. A list of excluded records with justifications for exclusion is available upon request. Most guidelines were rated as moderate or high quality, using the modified AGREE-II checklist⁸ (Supplemental Appendix 3). The number of guidelines included per clinical/diagnostic scenario ranged from 0 to 10, with a median of 3 guidelines per clinical scenario.

Recommendations

Additional details of the included guidelines, including which imaging modalities (eg, computed tomography [CT], magnetic resonance imaging [MRI], radiograph [XR], ultrasound [US]) that were discussed can be found in Supplemental Appendix 4.

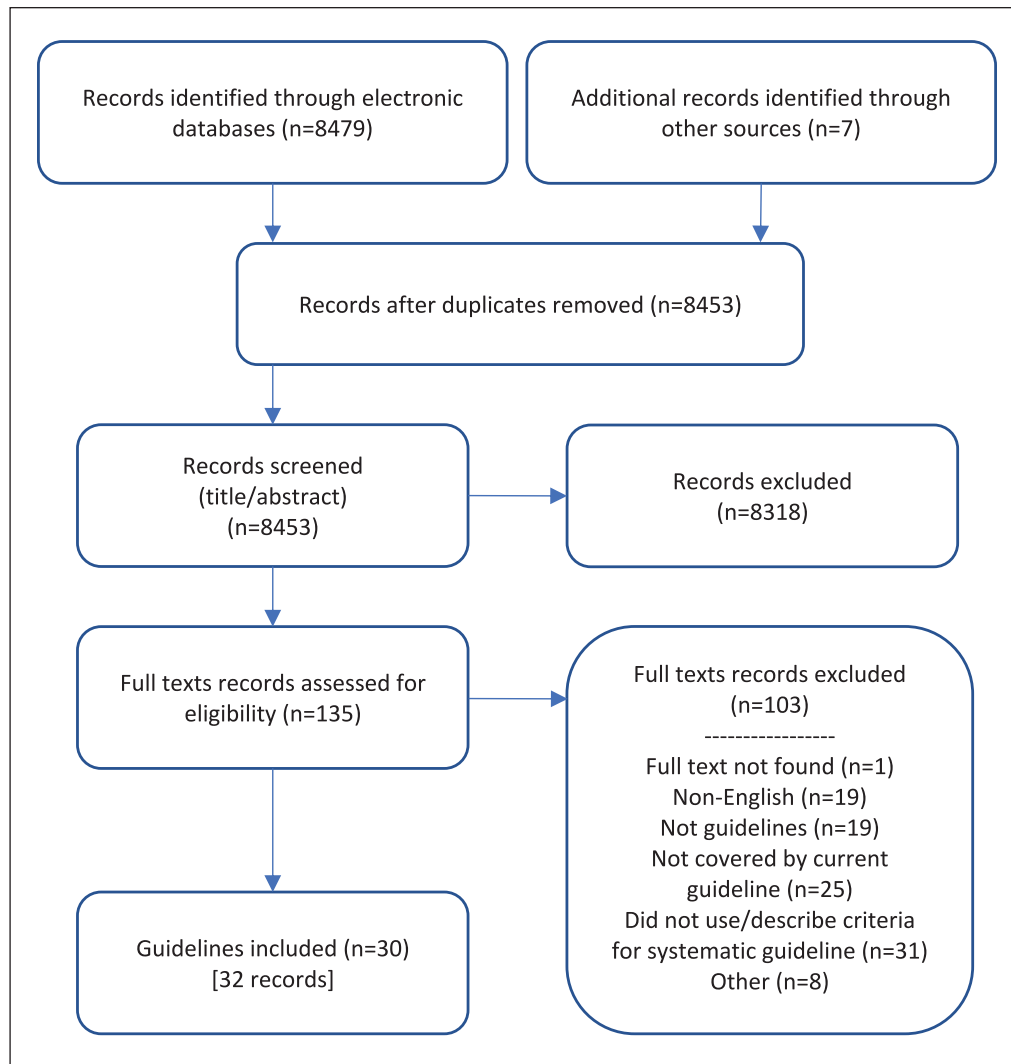


Figure 1. PRISMA flow diagram.

A guideline is intended to guide and not be an absolute rule. Medical care is complex and should be based on evidence, a clinician's expert judgment, the patient's circumstances, values, preferences, and resource availability. Not all imaging modalities are available in all clinical environments, particularly in rural or remote areas of Canada. Decisions about patient transfer, use of alternative imaging or serial clinical examination and observation can be complex and difficult. Therefore, the expected benefits of recommended imaging, risks of travel, patient preference, and other factors must be considered. The guideline recommendations are designed to assist the choice of imaging modality in situations where it is deemed clinically necessary to obtain imaging.

Recommendations do not specify when contrast should or should not be used, as this may vary based on clinical presentation, regional practice preferences, preference of the referring clinician, radiologist and/or the patient, and resource availability.

We reviewed relevant recommendations related to the 24 clinical/diagnostic scenarios previously published by radiology and specialty societies, including: the Canadian Association of Radiologists,⁹ the American College of Radiology,¹⁰⁻¹⁹ the American Thoracic Society and Infectious Diseases Society of America,²⁰ the CHEST Expert Panel,²¹⁻²³ the Emergency Medicine Association of Turkey/Turkish Thoracic Society,²⁴ the European Respiratory Society,²⁵ the Fleischner Society,^{26,27} the French Language Pulmonology Society,²⁸ the German S3 guideline,²⁹ the Indian Chest Society National College of Chest Physicians,³⁰ the Indian Society of Anesthaesiologists,³¹ the Italian intersociety consensus,^{32,33} the Korean guideline,³⁴ the National Institute for Health and Clinical Excellence,³⁵ the Polish recommendations for lung ultrasound in internal medicine,³⁶ the S2K guideline,³⁷ the combined guideline by the Société Française de Médecine d'Urgence, the Société de Réanimation de Langue Française and the French Group for Pediatric Intensive Care and

Table 2. Screening/Asymptomatic, Non-Specific Chest Pain, Long-Term Care, and Hospital Recommendations.

Clinical/ Diagnostic Scenario and Recommendations
TH01. SCREENING/ASYMPTOMATIC INDIVIDUALS
TH01A. Pre-employment screening ^{9,40}
<ol style="list-style-type: none"> 1. For most individuals we recommend against routine chest XR for pre-employment screening, except in specific circumstances (see Recommendation 2) (↓↓). 2. In individuals at high-risk for tuberculosis or in certain occupations (e.g., deep water divers), we recommend routine chest XR if one has not been done recently (↑↑). 3. In individuals with positive latent tuberculosis testing, we recommend chest XR to exclude active tuberculosis (↑↑).
TH01B. Asbestos exposure ¹⁰
<ol style="list-style-type: none"> 1. In asymptomatic individuals who have had occupational exposure to asbestos and require imaging for documentation or confirmation of injury, we recommend chest XR as the initial imaging modality (↑↑). <ul style="list-style-type: none"> ↳ 1.1 In individuals with equivocal chest XR and/or a high clinical suspicion for occupational lung disease, we recommend high-resolution CT as the next imaging modality (EP consensus).
TH01C. Routine in-patient radiographs
<ol style="list-style-type: none"> 1. In hospitalized patients, we recommend against routine chest XR (EP consensus).
<i>Refer to TH03 for Hospital admission for non-thoracic conditions.</i>
TH02. NON-SPECIFIC CHEST PAIN ^{9,11,40}
In patients with non-specific chest pain (non-cardiac origin), imaging should be guided by clinical assessment, ECG, and serum biomarkers.
<ol style="list-style-type: none"> 1. In stable patients where imaging is clinically or biochemically indicated, we recommend chest XR as the initial imaging modality (↑↑). <ul style="list-style-type: none"> ↳ 1.1 If the chest XR is normal or equivocal, we suggest that further investigations should be guided after clinical consideration of etiology[◇] (EP consensus).
[◇] For example, musculoskeletal, abdominal, pulmonary, cardiovascular, esophageal
TH03. HOSPITAL ADMISSION FOR NON-THORACIC CONDITIONS ^{9,12}
<ol style="list-style-type: none"> 1. In patients being admitted to hospital for non-thoracic conditions, we recommend against routine chest XR (↓↓).
TH04. LONG-TERM CARE ADMISSION ¹³
<ol style="list-style-type: none"> 1. In individuals who are being admitted to long-term care, we recommend referring to the local practice guidelines to guide imaging (↑↑).
TH05. ROUTINE PRE-OPERATIVE ^{9,12,31,40}
<ol style="list-style-type: none"> 1. In patients undergoing non-cardiothoracic surgery, we suggest against routine pre-operative chest XR (↓). 2. In patients undergoing cardiothoracic surgery, we suggest routine pre-operative chest XR (↑). 3. In frail elderly patients and in those with significant cardiorespiratory disease, we suggest routine pre-operative chest XR (↑).
TH06. POST-INTERVENTIONAL CHEST PROCEDURES ^{9,29,32}
<ol style="list-style-type: none"> 1. In patients who have undergone a chest procedure, including cardiothoracic surgery, we suggest routine post-interventional chest XR in situations where clinical judgement may not be sensitive to potential complications, including post transthoracic interventions (e.g., lung biopsy, central line, nasogastric tube, endotracheal tube placement, thoracentesis, chest tube, etc.) (↑).

ECG: electrocardiogram; EP: expert panel; XR: radiograph

Strength of Recommendation: ↑↑: strong for; ↑: conditional for; ↓: conditional against; ↓↓: strong against

Table 3. Upper Respiratory Tract Infections, Asthma, COPD, Pneumonia, Chronic Cough Recommendations.

Clinical/ Diagnostic Scenario and Recommendations
TH07. UPPER RESPIRATORY TRACT INFECTION^{9,40}
<ol style="list-style-type: none"> 1. In patients with uncomplicated upper respiratory tract infection, we recommend against chest XR (↓↓). <i>For recommendations on sinusitis, see Head and Neck clinical scenario H01A. Sinus disease: Acute and chronic sinusitis.</i> 2. In patients with clinical suspicion of pneumonia, acute tracheobronchitis with other comorbid conditions, we suggest chest XR as the initial imaging modality (↑).
TH08. ACUTE EXACERBATION OF ASTHMA^{9,38,40}
<ol style="list-style-type: none"> 1. In patients with acute asthma exacerbation <u>without</u> clinical concern for complications, we suggest against chest XR (↓). 2. In patients with acute asthma exacerbation <u>with</u> clinical concern for complications[◇], we recommend chest XR as the initial imaging modality (↑↑). <p>◇For example, clinical suspicion of pneumonia, suspected pneumomediastinum or pneumothorax, failure to respond to therapy</p>
TH09. ACUTE EXACERBATION OF COPD^{9,24,35,40}
<ol style="list-style-type: none"> 1. In patients with acute exacerbation of COPD who do not need a referral to hospital, we suggest against routine chest XR (↓). 2. In patients with acute exacerbation of COPD who are referred to hospital, we recommend chest XR as the initial imaging modality (↑↑). <ul style="list-style-type: none"> ↳ 2.1 In situations where chest XR is negative or indeterminate where there is persistent clinical concern or management might be altered, we suggest chest CT as the next imaging modality (↑).
TH10. SUSPECTED PNEUMONIA^{9,21,36,40}
<ol style="list-style-type: none"> 1. In stable outpatients with suspected pneumonia with a very high pre-test probability of pneumonia and when a chest XR would not alter management, we suggest against chest XR (↓). 2. In patients with abnormal vital signs secondary to suspected pneumonia, we recommend chest XR as the initial imaging modality (↑↑). <ul style="list-style-type: none"> ↳ 2.1 In patients with severe or complicated pneumonia (e.g., lung abscess, suspected empyema, or possible atypical organisms), we suggest chest CT as the next imaging modality (↑).
TH11. PNEUMONIA FOLLOW-UP^{9,20,40}
<ol style="list-style-type: none"> 1. In patients with clinical recovery of pneumonia, we do not recommend follow-up chest XR (↓↓). 2. In patients with persistent symptoms or physical signs of pneumonia or in those at higher risk of malignancy[◇], we suggest follow-up chest XR at least six weeks after treatment (↑). <ul style="list-style-type: none"> ↳ 2.1 In patients with no radiological or clinical resolution of pneumonia within the expected time (e.g., 8-12 weeks), we suggest chest CT as the next imaging modality (↑). <p>◇Smokers (>20 pack years), those >50 years old</p>
TH12. IMMUNOSUPPRESSED PATIENT WITH RESPIRATORY SYMPTOMS/ FEBRILE NEUTROPENIA^{9,14,39}
<ol style="list-style-type: none"> 1. In immunosuppressed patients with respiratory symptoms/febrile neutropenia, we recommend chest XR as the initial imaging modality (↑↑). <ul style="list-style-type: none"> ↳ 1.1 If chest XR is normal, equivocal, or inconclusive and there remains high clinical suspicion for pulmonary infection, we recommend low-dose chest CT as the next imaging modality (↑↑).
TH13. CHRONIC COUGH^{25,33}
Chronic cough is defined as a cough lasting 8 weeks or more.
<ol style="list-style-type: none"> 1. In patients with chronic cough, we recommend chest XR as the initial imaging modality (↑↑). <ul style="list-style-type: none"> ↳ 1.1 In patients with normal physical exam and chest XR, we suggest against routine chest CT (↓). ↳ 1.2 In patients with normal physical exam and chest XR and common causes of chronic cough have been excluded but there is ongoing clinical concern for etiology such as bronchiectasis, early interstitial lung disease, or lung cancer, we suggest chest CT as the next imaging modality (↑).
COPD: chronic obstructive pulmonary disease; CT: computed tomography; XR: radiograph
Strength of Recommendation: ↑↑: strong for; ↑: conditional for; ↓: conditional against; ↓↓: strong against

Table 4. Pneumothorax, Pleural Effusion, Hemoptysis, Chronic Dyspnea, Interstitial Lung Disease, Lung Nodule, Mediastinal Lesion, Mediastinal Lymphadenopathy, Elevated Diaphragm Recommendations.

Clinical/ Diagnostic Scenario and Recommendations
TH14. SUSPECTED PNEUMOTHORAX (NON-TRAUMATIC) ^{29,36,40}
1. In patients with suspected pneumothorax, we recommend erect inspiratory chest XR as the initial imaging modality (↑↑). ↳ 1.1 If chest XR findings are equivocal or indeterminate and further imaging is required, we suggest chest CT as the next imaging modality (↑).
TH15. CLINICALLY SUSPECTED PLEURAL EFFUSION ^{9,16,36,40}
1. In patients with clinically suspected pleural effusion, we recommend chest XR or bedside US (if available) as the initial imaging modality (↑↑). ↳ 1.1 If further imaging is required, we suggest chest CT as the next imaging modality (↑).
TH16. HEMOPTYSIS ^{9,17,34,40}
1. In patients with trace hemoptysis, we recommend chest XR as the initial imaging modality (↑↑). ↳ 1.1 In patients with risk factors [◇] or persistent/recurrent unexplained hemoptysis, we recommend chest CT as a complementary imaging modality (↑↑). 2. In patients with clinically significant hemoptysis, we recommend chest XR* and chest CT as the initial imaging modalities (↑↑). [◇] Smoker (e.g., >20 pack years), high risk of malignancy, >40 years * For baseline purposes
TH17. CHRONIC DYSPNEA OF NON-CARDIOVASCULAR ORIGIN ^{9,16,36}
1. In patients with chronic dyspnea of non-cardiovascular origin, we recommend chest XR as the initial imaging modality (↑↑). ↳ 1.1 If chest XR is normal and clinical concern remains, any decision for further imaging should be based on clinical grounds (EP consensus).
TH18. SUSPECTED INTERSTITIAL LUNG DISEASE ^{9,10,16,18,22,23,28,30,36,37,40}
1. In patients with suspected interstitial lung disease, we recommend chest XR as the initial imaging modality (↑↑). ↳ 1.1 If further imaging is required, given that chest XR does not rule out interstitial lung disease, we recommend high-resolution CT (HRCT) as the next imaging modality (↑↑).
TH19. INCIDENTAL LUNG NODULE ^{9,26,27,40}
1. In patients with an incidental lung nodule detected on chest CT [◇] , we recommend following the Fleischner Society Guidelines ²⁷ for Management of Incidental Pulmonary Nodules Detected on CT Images (↑↑). [◇] Excluding CT chest as part of lung cancer screening
TH20. SUSPECTED MEDIASTINAL LESION ^{9,19}
1. In patients with suspected mediastinal lesion, we recommend chest CT as the initial imaging modality (↑↑). ↳ 1.1 If further imaging is required to evaluate local invasion or to characterize tissue composition, we recommend chest MRI as the next imaging modality (↑↑).
TH21. SUSPECTED MEDIASTINAL LYMPHADENOPATHY ⁹
1. In patients with suspected mediastinal lymphadenopathy, we recommend chest CT as the initial imaging modality (↑↑).
TH22. ELEVATED DIAPHRAGM ON CHEST RADIOGRAPH ⁹
1. In patients with elevated diaphragm on chest XR and suspected phrenic nerve palsy, we suggest fluoroscopy or US as the initial imaging modality (↑).

CT: computed tomography; MRI: magnetic resonance imaging; US: ultrasound; XR: radiograph

Strength of Recommendation: ↑↑: strong for; ↑: conditional for; ↓: conditional against; ↓↓: strong against

Emergencies,³⁸ the Spanish Society of Medical Oncology,³⁹ and the Royal College of Radiologists.⁴⁰

Recommendations are presented in 3 tables: Non-specific chest pain, long-term care, and hospital-based scenarios (Table 2), Upper respiratory tract infections, asthma, chronic obstructive pulmonary disease (COPD), pneumonia, and chronic cough scenarios (Table 3), Pneumothorax, pleural effusion, hemoptysis, chronic dyspnea, interstitial lung disease, lung nodule, mediastinal lesion, mediastinal lymphadenopathy, and elevated diaphragm scenarios (Table 4).

Acknowledgments

We would like to thank: Becky Skidmore for creating the search strategies for the systematic scoping review, and the following individuals on the Diagnostic Imaging Referral Guidelines Working Group and external stakeholders for providing feedback on the guideline (listed alphabetically): Carole Dennie, Cameron Hague, Ryan Margau (WG co-chair), Cathy MacLean, Elsie Nguyen, Paul Pageau (WG co-chair), Erin Sarrazin, Carolina Souza, Jana Taylor, Charlotte Yong-Hing, and Kaitlin Zaki-Metias.

Declaration of Conflicting Interests

The author(s) declared no potential conflicts of interest with respect to the research, authorship, and/or publication of this article.

Funding

The author(s) disclosed receipt of the following financial support for the research, authorship, and/or publication of this article: This work was supported by the Canadian Medical Association.

ORCID iD

Candace Hamel  <https://orcid.org/0000-0002-5871-2137>

Supplemental Material

Supplemental material for this article is available online.

References

- Hamel C, Margau R, Pageau P, et al. Canadian Association of Radiologists diagnostic imaging referral guidelines: a guideline development protocol. *CMAJ Open*. 2023;11(2):E248-E254. doi:10.9778/cmajo.20220098
- Hamel C, Venturi M, Margau R, Pageau P. Canadian Association of Radiologists diagnostic imaging referral guidelines. *Can Assoc Radiol J*. 2023;74(4):614-615. doi:10.1177/08465371231169746
- Peters M, Godfrey C, McInerney P, Munn Z, Tricco A, Khalil H. Chapter 11: Scoping reviews. In: Aromataris E and Munn Z, eds. *JBIM Manual for Evidence Synthesis*. The Joanna Briggs Institute; 2020. Accessed February 24, 2021. <https://doi.org/10.46658/JBIMES-20-12>
- Higgins J, Thomas J, Chandler J, et al. *Cochrane Handbook for Systematic Reviews of Interventions Version 6.2 (Updated February 2021)*; 2021. Accessed October 23, 2023. www.training.cochrane.org/handbook
- Garrity C, Gartlehner G, Nussbaumer-Streit B, et al. Cochrane Rapid Reviews Methods Group offers evidence-informed guidance to conduct rapid reviews. *J Clin Epidemiol*. 2021;130:13-22. doi:10.1016/j.jclinepi.2020.10.007
- Andrews J, Guyatt G, Oxman AD, et al. GRADE guidelines: 14. Going from evidence to recommendations: the significance and presentation of recommendations. *J Clin Epidemiol*. 2013;66(7):719-725. doi:10.1016/j.jclinepi.2012.03.013
- Andrews JC, Schünemann HJ, Oxman AD, et al. GRADE guidelines: 15. Going from evidence to recommendation-determinants of a recommendation's direction and strength. *J Clin Epidemiol*. 2013;66(7):726-735. doi:10.1016/j.jclinepi.2013.02.003
- AGREE Next Steps Consortium. The AGREE II Instrument [Electronic Version]. Published 2017. Accessed March 3, 2022. <https://www.agreetrust.org/wp-content/uploads/2017/12/AGREE-II-Users-Manual-and-23-item-Instrument-2009-Update-2017.pdf>
- Canadian Association of Radiologists. *2012 CAR Diagnostic Imaging Referral Guidelines*. Canadian Association of Radiologists; 2012. Accessed July 5, 2021. <https://car.ca/patient-care/referral-guidelines/>
- Expert Panel on Thoracic Imaging, Cox CW, Chung JH, et al. ACR Appropriateness Criteria® occupational lung diseases. *J Am Coll Radiol*. 2020;17(5S):S188-S197. doi:10.1016/j.jacr.2020.01.022
- Expert Panel on Cardiac Imaging, Beache GM, Mohammed TLH, et al. ACR Appropriateness Criteria® acute nonspecific chest pain-low probability of coronary artery disease. *J Am Coll Radiol*. 2020;17(11S):S346-S354. doi:10.1016/j.jacr.2020.09.006
- Expert Panel on Thoracic Imaging, Bang T, Chung J, et al. ACR Appropriateness Criteria® routine chest imaging. *J Am Coll Radiol*. 2023;20:S224-S233.
- Expert Panel on Thoracic Imaging; Ravenel JG, Chung JH, et al. ACR Appropriateness Criteria® imaging of possible tuberculosis. *J Am Coll Radiol*. 2017;14(5S):S160-S165. doi:10.1016/j.jacr.2017.02.022
- Expert Panel on Thoracic Imaging, Lee C, Colletti PM, et al. ACR Appropriateness Criteria® acute respiratory illness in immunocompromised patients. *J Am Coll Radiol*. 2019;16(11S):S331-S339. doi:10.1016/j.jacr.2019.05.019
- Expert Panel on Thoracic Imaging, Kuzniewski CT, Kizhner O, et al. ACR Appropriateness Criteria® chronic cough. *J Am Coll Radiol*. 2021;18(11S):S305-S319. doi:10.1016/j.jacr.2021.08.007
- Expert Panel on Thoracic Imaging; McComb BL, Ravenel JG, et al. ACR Appropriateness Criteria® chronic dyspnea-noncardiovascular origin. *J Am Coll Radiol*. 2018;15(11S):S291-S301. doi:10.1016/j.jacr.2018.09.015
- Expert Panel on Thoracic Imaging, Olsen KM, Manouchehr-Pour S, et al. ACR Appropriateness Criteria® hemoptysis. *J Am Coll Radiol*. 2020;17(5S):S148-S159. doi:10.1016/j.jacr.2020.01.043
- Expert Panel on Thoracic Imaging; Hobbs SB, Chung JH, et al. ACR Appropriateness Criteria® diffuse lung disease. *J Am Coll Radiol*. 2021;18(11S):S320-S329. doi:10.1016/j.jacr.2021.08.008
- Expert Panel on Thoracic Imaging, Ackman JB, Chung JH, et al. ACR Appropriateness Criteria® imaging of mediastinal masses. *J Am Coll Radiol*. 2021;18(5S):S37-S51. doi:10.1016/j.jacr.2021.01.007

20. Metlay JP, Waterer GW, Long AC, et al. Diagnosis and treatment of adults with community-acquired pneumonia. An Official Clinical Practice Guideline of the American Thoracic Society and Infectious Diseases Society of America. *Am J Respir Crit Care Med*. 2019;200(7):e45-e67. doi:10.1164/rccm.201908-1581ST
21. Hill AT, Gold PM, El Solh AA, et al. Adult outpatients with acute cough due to suspected pneumonia or influenza: CHEST guideline and expert panel report. *Chest*. 2019;155(1):155-167. doi:10.1016/j.chest.2018.09.016
22. Fernández Pérez ER, Travis WD, Lynch DA, et al. Diagnosis and evaluation of hypersensitivity pneumonitis: CHEST guideline and expert panel report. *Chest*. 2021;160(2):e97-e156. doi:10.1016/j.chest.2021.03.066
23. Fernández Pérez ER, Travis WD, Lynch DA, et al. Executive summary: diagnosis and evaluation of hypersensitivity pneumonitis: CHEST guideline and expert panel report. *Chest*. 2021;160(2):595-615. doi:10.1016/j.chest.2021.03.067
24. Doğan NÖ, Varol Y, Köktürk N, et al. 2021 Guideline for the Management of COPD Exacerbations: Emergency Medicine Association of Turkey (EMAT) / Turkish Thoracic Society (TTS) Clinical Practice Guideline Task Force. *Turk J Emerg Med*. 2021;21(4):137-176. doi:10.4103/2452-2473.329630
25. Morice AH, Millqvist E, Bieksiene K, et al. ERS guidelines on the diagnosis and treatment of chronic cough in adults and children. *Eur Respir J*. 2020;55(1):1901136. doi:10.1183/13993003.01136-2019
26. Bueno J, Landeras L, Chung JH. Updated Fleischner Society guidelines for managing incidental pulmonary nodules: common questions and challenging scenarios. *Radiographics*. 2018;38(5):1337-1350. doi:10.1148/rg.2018180017
27. MacMahon H, Naidich DP, Goo JM, et al. Guidelines for management of incidental pulmonary nodules detected on CT images: from the Fleischner Society 2017. *Radiology*. 2017;284(1):228-243. doi:10.1148/radiol.2017161659
28. Cottin V, Bonniaud P, Cadranel J, et al. French practical guidelines for the diagnosis and management of idiopathic pulmonary fibrosis - 2021 update. Full-length version. *Respir Med Res*. 2022;83:100948. doi:10.1016/j.resmer.2022.100948
29. Schnell J, Beer M, Eggeling S, et al. Management of spontaneous pneumothorax and post-interventional pneumothorax: German S3-guideline. *Respiration*. 2019;97(4):370-402. doi:10.1159/000490179
30. Singh S, Sharma BB, Bairwa M, et al. Management of interstitial lung diseases: a consensus statement of the Indian Chest Society (ICS) and National College of Chest Physicians (NCCP). *Lung India*. 2020;37(4):359-378. doi:10.4103/lungindia.lungindia_275_20
31. Umesh G, Bhaskar SB, Harsoor SS, et al. Preoperative investigations: practice guidelines from the Indian Society of Anaesthesiologists. *Indian J Anaesth*. 2022;66(5):319-343. doi:10.4103/ija.ija_335_22
32. Piccioni F, Droghetti A, Bertani A, et al. Recommendations from the Italian intersociety consensus on Perioperative Anesthesia Care in Thoracic surgery (PACTS) part 2: intraoperative and postoperative care. *Perioper Med (Lond)*. 2020;9:31. doi:10.1186/s13741-020-00159-z
33. De Vincentis A, Baldi F, Calderazzo M, et al. Chronic cough in adults: recommendations from an Italian intersociety consensus. *Aging Clin Exp Res*. 2022;34(7):1529-1550. doi:10.1007/s40520-022-02154-4
34. Kang MJ, Kim JH, Kim YK, et al. 2018 Korean clinical imaging guideline for hemoptysis. *Korean J Radiol*. 2018;19(5):866-871. doi:10.3348/kjr.2018.19.5.866
35. NICE. *Chronic Obstructive Pulmonary Disease in Over 16s: Diagnosis and Management*. National Institute for Health and Care Excellence (NICE); 2018. Accessed November 30, 2022. www.nice.org.uk/guidance/ng115
36. Buda N, Kosiak W, Welnicki M, et al. Recommendations for lung ultrasound in internal medicine. *Diagnostics (Basel)*. 2020;10(8):597. doi:10.3390/diagnostics10080597
37. Behr J, Günther A, Bonella F, et al. S2K guideline for diagnosis of idiopathic pulmonary fibrosis. *Respiration*. 2021;100(3):238-271. doi:10.1159/000512315
38. Le Conte P, Terzi N, Mortamet G, et al. Management of severe asthma exacerbation: guidelines from the Société Française de Médecine d'Urgence, the Société de Réanimation de Langue Française and the French Group for Pediatric Intensive Care and Emergencies. *Ann Intensive Care*. 2019;9(1):115. doi:10.1186/s13613-019-0584-x
39. Carmona-Bayonas A, Jimenez-Fonseca P, de Castro EM, et al. SEOM clinical practice guideline: management and prevention of febrile neutropenia in adults with solid tumors (2018). *Clin Transl Oncol*. 2019;21(1):75-86. doi:10.1007/s12094-018-1983-4
40. The Royal College of Radiologists. *RCR iRefer Guidelines: Making the Best Use of Clinical Radiology*. The Royal College of Radiologists; 2017.