

Frey's Syndrome: A Case of Aberrant Nerve Regeneration

Jason G. Williams¹, B.Sc., MD '00, and Mark E. P. Prince², MD, FRCSC

¹ Dalhousie University Faculty of Medicine, Halifax, Nova Scotia

² Department of Otolaryngology-Head and Neck Surgery, Queen Elizabeth II Health Sciences Centre, Halifax, Nova Scotia

Frey's syndrome represents a fascinating example of how nerve regeneration can go awry. The syndrome is characterized by profuse facial sweating and flushing that occurs when salivation is stimulated. It can develop following a variety of insults, but is most commonly encountered as a complication of parotidectomy. Consequently, it is mainly otolaryngologists who see and treat this disorder; however, it is important for other clinicians to recognize what these unusual symptoms represent. Diagnosis may be based either on clinical presentation or through objective testing methods. Potential negative social and psychological implications of this condition can be significant, and treatment, ranging from topical agents, to local injections of botulinum toxin (Botox), to surgical intervention should be offered to patients. In this article, we present a clinical case and review the etiology of Frey's syndrome, its diagnosis and treatment.

INTRODUCTION

Profuse sweating and flushing over the preauricular and parotid regions of the face during mastication constitutes the symptom complex known as Frey's syndrome (1). Also referred to as auriculotemporal syndrome or gustatory sweating, it is most commonly encountered in post-parotidectomy patients. Its incidence is not known for certain, but it is estimated that approximately 50% of post-parotidectomy patients will report symptoms, while over 90% will test positive for gustatory sweating using objective tests. Symptoms usually become apparent within several months of surgery (1,2).

Duphenix, a French surgeon, first described this entity in 1757 after observing gustatory sweating following the drainage of a parotid abscess (3). The syndrome was named for the Polish neurologist Lucja Frey. In 1923, Frey described the occurrence of gustatory sweating in a patient who had sustained a gunshot wound to the parotid region (4,5).

The pathophysiology of Frey's syndrome is believed to have its origins intra-operatively, when postganglionic parasympathetic cholinergic secretomotor

fibers, which normally innervate the parotid gland, are severed during parotidectomy (1). The severed fibers then undergo abnormal regeneration of the cut ends of post-ganglionic cholinergic sympathetics to the sweat glands of the overlying skin (1,6). Because of these aberrant neural connections, when salivation is stimulated, local sweat glands are inadvertently activated and the patient's cheek becomes flushed and wet.

CASE REPORT

A 68-year-old man presented with a left cheek mass that had been present for several years and was growing slowly. He had no other symptoms, had not noticed any pain or facial weakness, and denied any fluctuation in size. Examination revealed a well-circumscribed 3 cm mass in the tail of the left parotid gland. His facial nerve was intact and the remainder of the exam was normal. Fine needle aspiration revealed some atypical cells, but was not diagnostic of a specific pathology. A left superficial parotidectomy was performed preserving the facial nerve. Final pathology identified a Warthin's tumour. His post-operative course was uncomplicated. Approximately 5 months after his surgery he began to note that his left cheek felt sweaty and flushed during meals. He returned to clinic and was diagnosed with Frey's syndrome based on history. Treatment with 20% aluminum chloride topical antiperspirant improved his symptoms.

Address correspondence to:

Jason Williams, Box 91, Sir Charles Tupper Medical Building, Dalhousie University, Halifax, NS B3H 4H7

DISCUSSION

The majority of cases of Frey's syndrome occur in post-parotidectomy patients. It has also been observed in other situations. Historically, it can be noted that Frey's original description of gustatory sweating was in a patient who had received trauma to the parotid region (4,5). Some incidental reports in recent literature include a case report by Mellor describing Frey's syndrome following the fracture of the mandibular condyle (7), and a report by Beale discussing the development of Frey's syndrome after chemotherapy for testicular teratoma (8).

Anatomy and Pathophysiology

Appreciation of the normal innervation of the parotid gland region is critical to understanding the significance of the aberrant neuronal regeneration associated with Frey's syn-

drome. The ninth cranial nerve (glossopharyngeal) is the source of secretomotor stimulation to the parotid gland (**Figure 1**). These fibers originate in the brainstem within the inferior salivary nucleus and exit the skull through the foramen ovale, near the mandibular branch of the trigeminal nerve. The glossopharyngeal nerve descends between the jugular vein and the carotid artery, receiving sympathetic fibers from the carotid plexus. It then loops forward, giving off the tympanic nerve which enters the middle ear cavity. These preganglionic parasympathetic fibers within the lesser superficial petrosal nerve synapse with cell bodies of second order neurons that comprise the otic ganglion. From the otic ganglion, postganglionic fibers travel with the auriculotemporal branch of the mandibular branch of the trigeminal nerve. In the parotid region the cholinergic secretomotor fibers leave the auriculotemporal nerve and diffusely innervate the parotid gland (1,10). Sympathetic innervation originates at the superior cervical ganglion of the sympathetic chain, where fibers leave

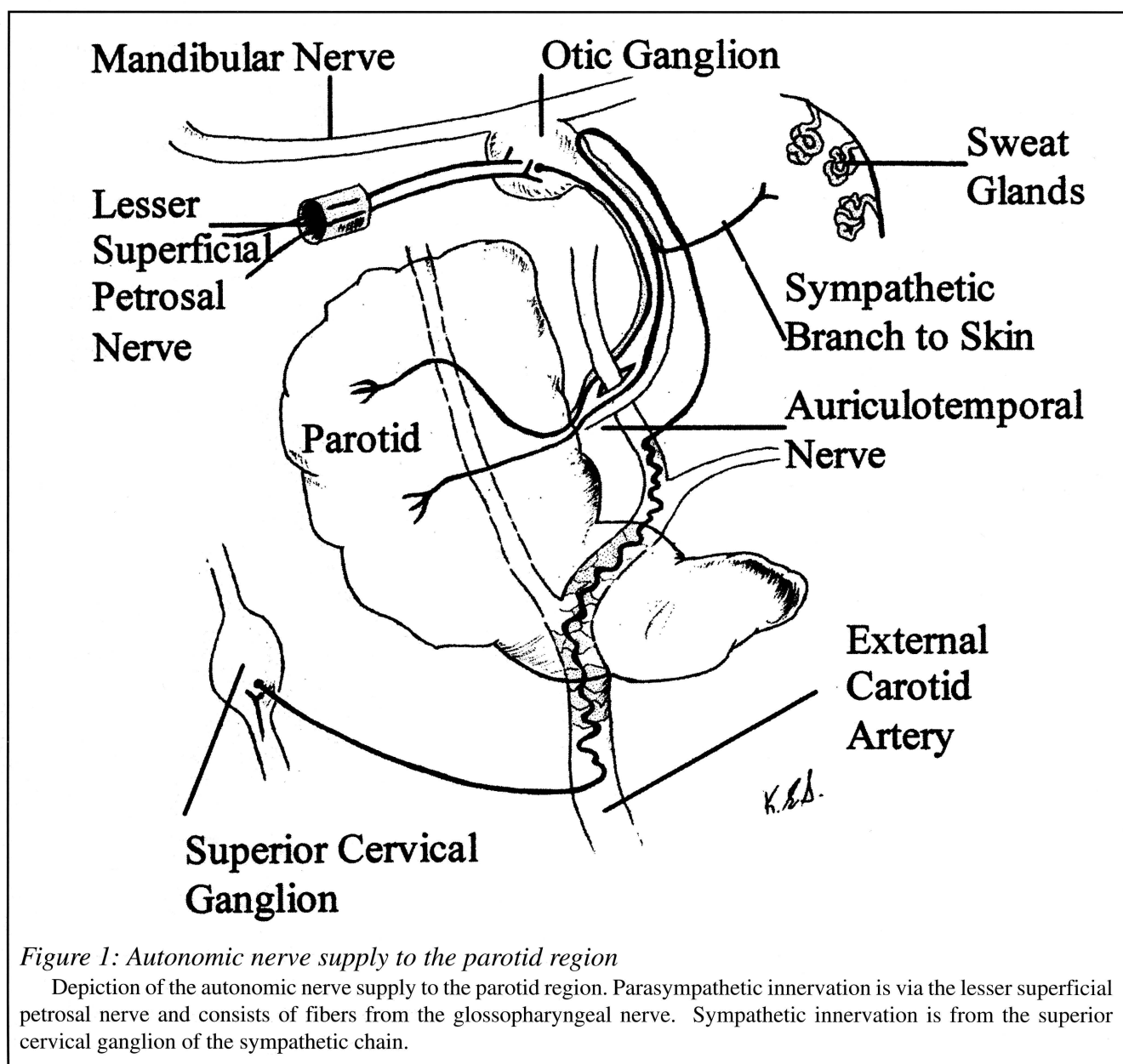


Figure 1: Autonomic nerve supply to the parotid region

Depiction of the autonomic nerve supply to the parotid region. Parasympathetic innervation is via the lesser superficial petrosal nerve and consists of fibers from the glossopharyngeal nerve. Sympathetic innervation is from the superior cervical ganglion of the sympathetic chain.

Table 1: Treatment options for Frey's Syndrome

Treatment	Agent/Method
<i>Topical Antiperspirants</i> (1,6)	20% Aluminum Chloride in alcohol Scopolamine cream Glycopyrrolate lotion
<i>Local Injections</i> (13,17,18)	Botulinum toxin type A (BOTOX) injections
<i>Surgical Intervention</i> (1,6,11)	Tympanic neurectomy Fascia Lata Graft Rotation of SCM muscle flap
<i>Prophylactic Intra-operative</i> (1,6, 4)	Preserve auriculotemporal nerve Raise thick skin flap Fascia lata graft Superficial musculoaponeurotic system (SMAS) interposition

to travel along with the external carotid artery to the parotid gland and skin. The sympathetic fibers that innervate cutaneous capillaries and sweat glands also use the neurotransmitter acetylcholine (10).

The most widely accepted mechanism of Frey's syndrome is aberrant neuronal regeneration (1,2,5,6,11,12). During parotidectomy the postganglionic parasympathetic nerves supplying the parotid gland are sectioned. Also interrupted are the sympathetic fibers that supply local sweat glands (10,13). Following the surgery, it is believed that the severed parasympathetic fibers regenerate to connect with severed distal sympathetic nerve fibers that innervate subcutaneous sweat glands and cutaneous blood vessels. When the inferior salivary nucleus is stimulated, the output previously destined for the salivary gland now stimulates sweat glands in the distribution area of the auriculotemporal nerve (1,13). This cross-regeneration between parasympathetic and sympathetic nerve fibers is only possible because both use acetylcholine as a neurotransmitter in this area.

The diagnosis of Frey's syndrome can often be made clinically, based on reported symptoms. The most common objective test for Frey's syndrome is Minor's starch/iodine test. The suspected area of the patient's face is painted with an iodine solution, then allowed to dry. The area is dusted with starch powder, and the patient is given a sialogogue such as a lemon wedge. If gustatory sweating occurs, dark blue-black spots will appear as the sweat dissolves the starch powder and it reacts with iodine (1,15). Minor's test is considered to be very accurate, and is capable of identifying Frey's syndrome in asymptomatic patients. Eisele describes a method using facial tissue. Patients are given sialogogues, then one ply of a two-ply facial tissue is placed against the suspected area of the face. Wet areas on the tissue will identify affected areas of skin and unaffected areas will remain dry (15). Medical thermography was used by Isogai to successfully diagnose Frey's syndrome. Infrared thermography is performed before and after administration of a sialogogue. If Frey's syn-

drome is present, a cold spot will appear over the operative site while the opposite side of the face will remain at normal body temperature (16).

The decision to treat Frey's syndrome is based on the level of distress the symptoms cause the patient (1,5). Frequently patients with mild symptoms will opt for no treatment; however, if treatment is desired, then medical therapy will normally provide acceptable relief of sweating in most cases. A variety of topical antiperspirants have been used, including application of 3% scopolamine hydrobromide cream, 20% aluminum chloride in anhydrous ethyl alcohol, and roll-on glycopyrrolate lotion (1,6).

Recently, local intra-dermal injections with Botulinum Toxin Type A (Botox), which blocks the release of acetylcholine at cholinergic synapses, has been shown to be effective for treatment of moderate to severe Frey's syndrome. Laskawi *et al.* suggest that Botox injections should be the therapy of choice for severe Frey's syndrome (17,18). Despite eventual recurrence in many patients, the minimally invasive nature of this procedure and the long-term, symptom-free period make this treatment an attractive option. Laccourre *et al.* confirmed Laskawi's results, demonstrating relief of facial sweating within 2 days of injection and no recurrence during the 7-month follow-up period. The only side effect of note was a slight weakness of the upper lip in 2 patients. These investigators concluded that Botox injection is a valuable treatment option for patients who have Frey's syndrome following conservative parotidectomy (13). A potential serious complication of this therapy is transient facial nerve paralysis resulting from diffusion of toxin from the dermis to the facial nerve. While Laccourre *et al.* reported only mild facial nerve palsy that completely resolved within 3 months, it raises the important point that this intervention is not entirely benign. Cost of Botox therapy can be many times that of more conservative treatment, and cost-effectiveness will have to be demonstrated before it gains widespread favour.

If symptoms are severe and medical therapy is either ineffective or has unacceptable side effects, surgery may be considered. Tympanic neurectomy has been successful (1,5,11,14). The procedure involves disrupting the parasympathetic nerve fibers as they travel through the middle ear space. In 1962, Golding-Wood reported satisfactory resolution of Frey's syndrome in patients undergoing this procedure (11). Other surgical procedures have been proposed, including subdermal insertion of fascia lata grafts, and the rotation of sternocleidomastoid muscle flaps into the parotid bed (1,6,14). These techniques are based on the premise that introduction of a barrier between the sweat glands and the regenerating nerve fibers will prevent inappropriate connections from occurring. Successful resolution of Frey's syndrome using such procedures has been reported (6,14). Fascia lata grafts, rotation of muscle flaps, and reconstruction of the parotid bed with superficial musculoaponeurotic system (SMAS) interposition have been effective, and may be used prophylactically during the original surgery. Variation of surgical technique that preserves a thick skin flap and the auriculotemporal nerve has been reported to decrease the incidence of Frey's syndrome, but these are not practical in all cases (6,14).

CONCLUSION

Frey's syndrome is an interesting illustration of how misdirected nerve regeneration can manifest clinically. Frey's syndrome has the potential to cause great social distress for the patient, and the potential exists for negative psychological consequences. For this reason, it is important for not only otolaryngologists, but also general practitioners to be aware of this disorder and to be able to counsel patients on available treatments. Recent advances in treatment involving the use of Botulinum toxin injections are significant in that this can provide effective, minimally invasive, relatively long-lasting relief to sufferers of Frey's syndrome. Further study of Botox injections will be required to examine potential adverse effects such as facial nerve paralysis, long-term effectiveness, and cost-effectiveness before this treatment gains widespread acceptance.

ACKNOWLEDGEMENTS

Thanks to Ellen Sears for making her artistic abilities available to us in the creation of Figure 1, and to Dr. Michele Carr for her advice on this review.

REFERENCES

- Kaplan MJ, Johns ME. Malignant neoplasms. In: Cummings CW, ed. *Otolaryngology- Head and Neck Surgery*, 2nd ed. Toronto: Mosby, 1993:1043-1078.
- Linder TE, Huber A, Schmid S. Frey's syndrome after parotidectomy: a retrospective and prospective analysis. *Laryngoscope* 1997;107:1496-1501.
- Duphenix M. Observations sur les fistules du canal salivaire de Stenson. I. Sur une playe compliquee a la joue ou le canal salivaire fut déchiré. *Mem Acad R Chir* 1757;3:431-9.
- Frey L. Le syndrome du nerf auriculotemporal. *Rev Neur (Fr)* 1923;30:97-104.
- Harper KE, Spielvogel RL. Frey's syndrome. *Int J Dermatology* 1986;25:524-526.
- Webster K. Early results using a porcine dermal collagen implant as an interpositional barrier to prevent recurrent Frey's syndrome. *Br.J. Oral and Maxillofacial Surgery*. 1997; 35:104-106.
- Mellor TK. Frey's syndrome following fracture of the mandibular condyle: case report and literature review. *Injury* 1996;27:359-60.
- Beale P. Frey's syndrome after cisplatin-based chemotherapy for testicular teratoma (letter). *Ann Oncol* 1998;9:118-9.
- Laccourreye H, Laccourreye O, Cauchois R et al.. Total conservative parotidectomy for primary benign pleomorphic adenoma of the parotid gland: a 25 year experience with 229 patients. *Laryngoscope* 1994;104:1487-1494.
- Shaheen OH. Anatomy and physiology of the salivary glands. In: Kerr AG, ed. *Scott-Brown's Otolaryngology 5th ed: Basic Sciences*. Toronto: Butterworth's, 1987:232-244.
- Golding-Wood PH. Tympanic neurectomy. *J Laryngol Otol* 1962;76: 683-693.
- Novotny GM. Gustatory sweating and related syndromes. *J Otolaryngol*. 1976;5:251-255.
- Laccourreye O, Muscatelo L, Bonan B, Naude C, Brasnu D. Botulinum Toxin Type A for Frey's syndrome: a preliminary prospective study. *Ann Otol Rhinol Laryngol* 1998;107:52-55.
- Allison GR, Rappaport I. Prevention of Frey's syndrome with superficial musculoaponeurotic system interposition. *Am. J. Surgery* 1993;166: 407-410.
- Eisele DW. Simple method for the assessment of Frey's syndrome. *Laryngoscope* 1992;102:583-584.
- Isogai N. Application of medical thermography to the diagnosis of Frey's syndrome. *Head Neck* 1997;19:143-7.
- Drobic C, Laskawi R. Frey's syndrome: treatment with botulinum toxin. *Acta Otolaryngol Stockh*. 1995;115:459-461.
- Laskawi R, Drobic C, Schonebeck C. Up-to-date report of Botulinum Toxin Type A treatment in patients with gustatory sweating (Frey's syndrome). *Laryngoscope* 1998;108:381-384.

AUTHOR BIOGRAPHY

Jason Williams is a third year medical student at Dalhousie. Originally from Pictou County, NS, he attended Acadia University and participated in amphibian physiology research prior to entering Medical School.