



OPEN ACCESS

# Coil migration through two flow-diverting stents

Patrick Scott Rogers,<sup>1</sup> David Volders,<sup>2</sup> Gwynedd Pickett,<sup>3</sup> Robert Vandorpe<sup>2</sup>

<sup>1</sup>Diagnostic Imaging, Dalhousie University Faculty of Medicine, Halifax, Nova Scotia, Canada

<sup>2</sup>Diagnostic Imaging, Dalhousie University, Halifax, Nova Scotia, Canada

<sup>3</sup>Neurosurgery, Dalhousie University, Halifax, Nova Scotia, Canada

## Correspondence to

Dr Patrick Scott Rogers; pt319294@dal.ca

Accepted 24 December 2023

## SUMMARY

We report a case of a patient who initially presented with a subarachnoid haemorrhage secondary to a ruptured supraclinoid internal carotid artery (ICA) blister aneurysm. The patient was treated successfully with a flow diverter stent (FD) and coiling; however, a large aneurysm recurrence via a feeding posterior communicating artery (PCOM) was noted on the 1-year follow-up angiogram. During the retreatment, a second FD in the ICA resulted in insufficient aneurysm stasis. Therefore, the decision was made to coil sacrifice the PCOM via posterior circulation access. During the first coil deployment, the distal coil end migrated through the mesh of two overlapping FD into the middle cerebral artery. This complication was a previously unrecognised possibility given the composition of the FD. This case report aims to discuss this process as a potential complication during neurointerventional procedures using these devices.

## BACKGROUND

There are multiple different types of intracranial aneurysms (IA), one of which is the blood blister aneurysm (BBA). These are defined as an aneurysm with a broad base originating from a non-branching site of the internal carotid artery (ICA) terminus.<sup>1</sup> BBA is rare, accounting for 0.9%–6.5% of all IA and are highly prone to spontaneous rupture.<sup>2,3</sup>

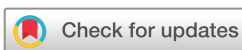Given their broad-based morphology, BBA is preferentially treated with a flow diverter (FD) to alter regional haemodynamics and disrupt intra-aneurysmal flow.<sup>4</sup> One type of FD is the Pipeline FD (Medtronic, Minneapolis, Minnesota, USA), which is made of a 75% cobalt chromium and 25% platinum tungsten braided mesh.<sup>5</sup> FD is known to offer safe and effective treatment of ICA aneurysms and demonstrates high rates of complete aneurysmal occlusion with low rates of adverse neurological events.<sup>6–10</sup>

FD is often used in concert with coil packing during a technique called stent-assisted coiling (SAC), a technique that has gained popularity in the treatment of wide-necked, fusiform, gigantic and complex IAs.<sup>11</sup> Coils may pass through the internal lumen of an FD once it is deployed. However, the FD fibres are arranged in a compact mesh weave that should prevent penetration of the stent wall by embolisation coils. This case concerns the migration of a coil through two overlapping FD, a technical complication that to our knowledge has not been previously described in the neurointerventional literature.

## CASE PRESENTATION

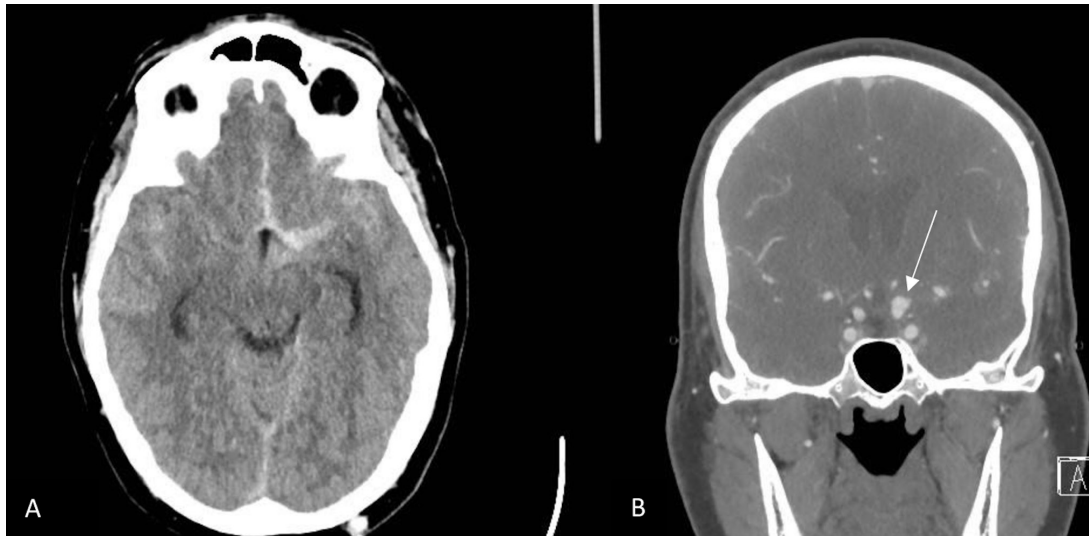
A previously healthy man in his 40s presented to hospital with a sudden-onset thunderclap headache. A CT scan showed subarachnoid haemorrhage, necessitating transfer to a nearby tertiary care facility to undergo further imaging and intervention (figure 1A). The following day a cerebral angiogram was conducted and a ruptured 3 mm wide necked left supraclinoid ICA blister aneurysm was found (figure 1B). Marksman 135 cm (Medtronic, Minneapolis) and SL-10 straight tip 150 cm (Stryker, Kalamazoo, Michigan, USA) microcatheters were used for delivery of the FD and embolisation coils, respectively. An FD Pipeline Flex 4.75×18 mm (Medtronic) was partially deployed and the embolisation coils were inserted into the aneurysm (figure 2A,B). This was followed by the complete deployment of the FD in the conventional SAC technique (figure 3). In total, 8 Microvention Microplex and 10 coils (Aliso Viejo, California, USA) were necessary to achieve aneurysm stasis. Although this may seem to be an excessive number of coils, operators decided to deploy a larger number of smaller coils due to concerns about losing access to the aneurysm with the microcatheter. There was complete obliteration (Raymond-Roy class 1) with the FD landing zone running from the ICA terminus to the cavernous ICA.

A diagnostic cerebral angiogram 1 year later showed a 7 mm recurrence of the aneurysm supplied by a large posterior communicating artery (PCOM) (figure 4). Due to the size and rapidity of the aneurysm's recurrence, it was classified as a dissecting aneurysm, which would explain why the initial treatment was ineffective. A plan was made to address the recurrent aneurysm with repeat FD insertion and potential PCOM vessel sacrifice. Alternatively, placing an FD within the PCA would have also occluded the PCOM, however, there was not any appropriately sized FD available at that time. To this effect, a Phenom 27 (Medtronic) microcatheter was advanced past the blister aneurysm and a second Pipeline Flex 4.5×16 mm FD was successfully deployed within the first FD from the carotid terminus to the cavernous ICA, again covering the neck of the aneurysm. Despite the second FD covering the aneurysm, there was still insufficient aneurysm stasis. Therefore, the plan was to access the aneurysm from the posterior circulation via the feeding PCOM with a SL-10 microcatheter and coil the aneurysm recurrence. Unfortunately, the microcatheter was not able to advance from the distal PCOM into the aneurysm and the decision was made to coil from that location to occlude inflow from the distal PCOM. It was reasoned that this manoeuvre was safe because the ICA was protected by the two FDs. During



© BMJ Publishing Group Limited 2024. Re-use permitted under CC BY-NC. No commercial re-use. See rights and permissions. Published by BMJ.

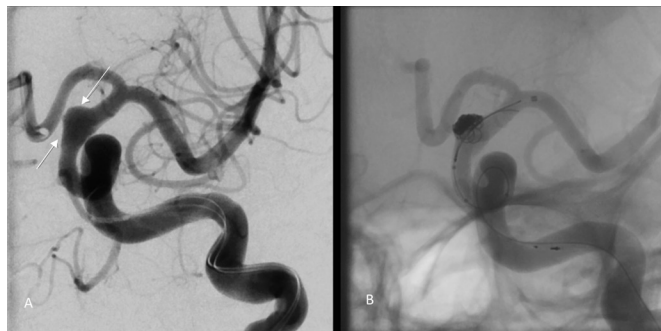**To cite:** Rogers PS, Volders D, Pickett G, et al. *BMJ Case Rep* 2024;**17**:e256863. doi:10.1136/bcr-2023-256863



**Figure 1** Initial unenhanced axial CT image of the brain demonstrating diffuse SAH (A). Coronal angiographic CT image of the supraclinoid ICA showing a large left BBA (B—white arrow). ICA, internal carotid artery; SAH, subarachnoid haemorrhage.

the deployment of the first Axium Prime 4×12 mm helical coil (Medtronic) distal coil migration through the mesh of the superimposed FD into the left M1 over a length of approximately 3.0 cm was seen (figure 5A,B). The coil migrated quickly into the FD lumen, puncturing through the FD mesh as if under tension (figure 6A,B). The coil then began to pulsate with each heartbeat, confirming that it was not jailed between the FD and the vessel wall. Unsuccessful retrieval efforts with a microsnare resulted in stretching of the proximal part of the coil. To correct this, a third Pipeline Flex 4.75×18 mm FD was partially deployed into the mid-M1 segment which secured the distal migrant coil loop. While pulling back the FD, the coil was captured and brought back into the ICA terminus. The rest of the FD was then fully deployed, jailing the coil between the second and third FD, covering the aneurysm neck.

Using a microsnare, much of the coil was retrieved. A control angiogram demonstrated more stagnation of contrast within the aneurysm, and the decision was made to not reattempt the PCOM sacrifice as the patient had already received a large dose of radiation. During the removal of the instruments, a control run demonstrated a flow-limiting dissection from the distal V3 to the proximal V4 segment with a growing pseudoaneurysm. A Pipeline Flex 5×35 mm FD was deployed covering the dissection. A control angiogram demonstrated complete recanalisation

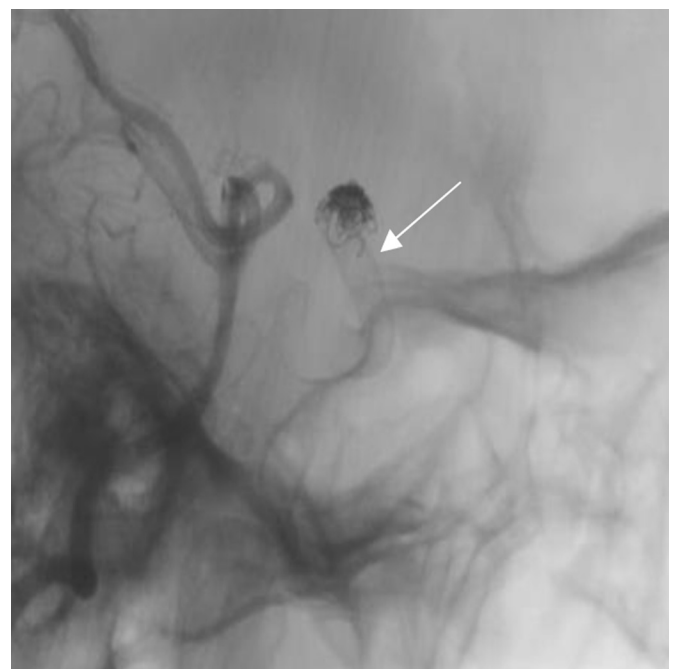


**Figure 2** Left AP ICA angiogram demonstrating the BBA (A, white arrows). Fluoroscopic AP image after a left ICA angiogram showing stent assisted coiling of the BBA (B). BBA, blood blister aneurysm; ICA, internal carotid artery.

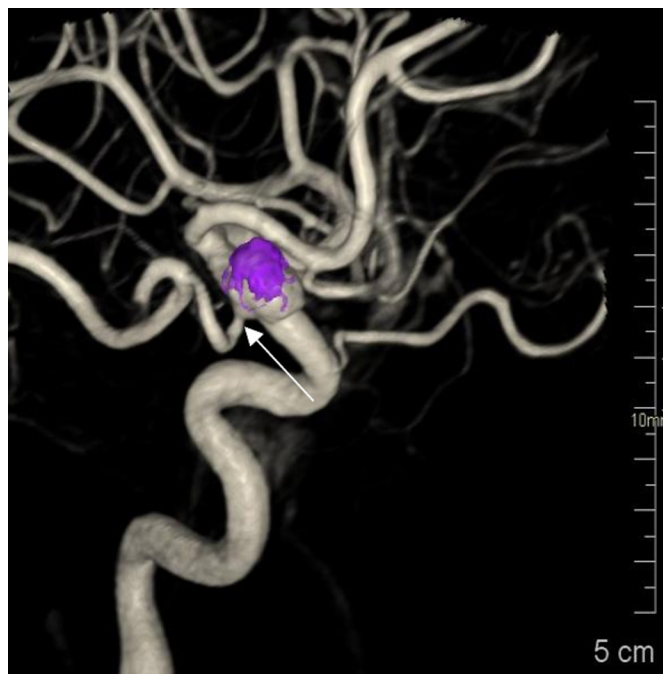
of the dominant left vertebral artery. A final control angiogram from the left vertebral artery and the left CCA did not demonstrate any distal emboli.

#### OUTCOME AND FOLLOW-UP

The following day the patient developed right arm weakness and aphasia. Small infarcts were found within the left basal ganglia, frontal lobe and cerebellum. The patient made a full neurological recovery. Given the persistent presence of the aneurysm despite the placement of three FD, the patient subsequently underwent open surgery with successful aneurysm clipping 2 weeks later. The patient's clinical condition did not change over the next 3 years, and he continues to be well (figure 7).



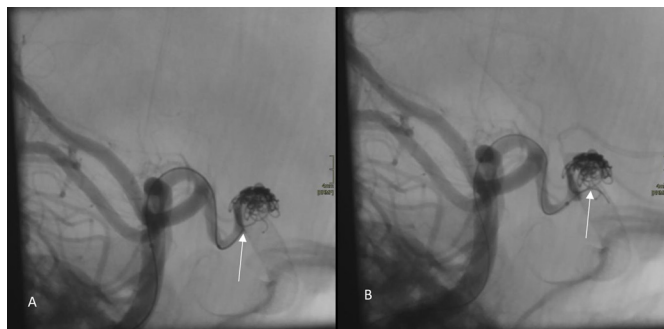
**Figure 3** Lateral fluoroscopic image post left vertebral artery injection demonstrating the presence of an FD within the ICA (white arrow). FD, flow diverter; ICA, internal carotid artery.



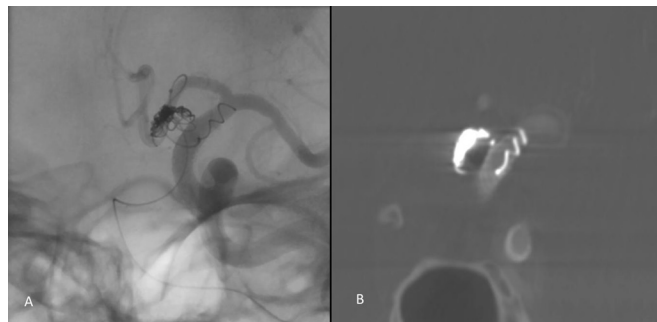
**Figure 4** Three-dimensional reconstruction after spin angiography of the left ICA demonstrating the recurrent aneurysm with a feeding PCOM (white arrow). The purple density depicts the location of the previously placed coils. ICA, internal carotid artery; PCOM, posterior communicating artery.

## DISCUSSION

Migration of embolisation coils through the mesh of an FD is a potentially serious complication that has not been well studied or indeed reported. The nominal diameter of an Axiom Prime 4×12 mm helical coil tip is 0.012 inches (305 µm). The pore size for the Pipeline Flex FD is a range between 200 and 300 µm depending on the size of the vessel it is deployed within. Assuming the FD was deployed in a large intracranial vessel (ICA), allowing for the pore size to reach the maximum extent. This means that the coil tip is still unlikely to pass through the wall of the stent given that the coil is always larger than the pore diameter. However, if force is applied and the angle is optimised, the wires in the braid will move to accommodate the pressure imposed by the coil. In our case, the vessel contained



**Figure 5** Lateral fluoroscopic image after a left vertebral artery angiogram demonstrating the final position of the coil before penetration into the FD (A—white arrow). A second lateral fluoroscopic image demonstrates the coil migration through the FD mesh into the ICA lumen (B—white arrow). FD, flow diverter; ICA, internal carotid artery.



**Figure 6** AP fluoroscopic image after a left ICA angiogram (A) and a coronal dyna-CT image from the left ICA demonstrates further migration of the coil through the FD into the ICA (B). AP, anterior-posterior; FD, flow diverter; ICA, internal carotid artery.

two superimposed FD, which made it even more unlikely for migration to occur as the coil had to pass through two barriers in this fashion.

We propose two factors that may have contributed to this complication. The first is the angle of approach. When the coil was deployed, the microcatheter delivery system was placed at a 90° angle from the PCOM in relation to the FD in the ICA. If the microcatheter had been placed at an angle away from the stent, as is done during most stent-jail techniques, the coil loop may have instead rebounded off the side of the FD. The second factor is support. When the coil was delivered, the microcatheter was near-adjacent to the FD. In this configuration, the microcatheter was able to stabilise the coil and keep it straight until it penetrated the FD. If the coil had been delivered farther away from the FD, it likely would have started breaking into loops which would have reduced the likelihood of penetration.

In conclusion, the unexpected migration of an embolisation coil through the wall of an FD may have serious consequences for patient safety. Interventionalists should be aware of this possibility when embolising an aneurysm adjacent to an FD, and if possible, select a microcatheter position that may reduce the risk.



**Figure 7** Three-dimensional reconstruction after spin angiography of the left ICA showing no significant aneurysm on follow-up 3 years later. ICA, internal carotid artery.



## Learning points

- ▶ A coil can migrate through the mesh wall of a flow diverter (FD).
- ▶ Penetration of an FD with coils may become more likely when the coil is supported by a microcatheter positioned perpendicularly to the FD, particularly at close range.
- ▶ An FD can be partially deployed and retracted to retrieve and jail a distally migrated coil loop.

**Contributors** The following authors were responsible for drafting of the text, sourcing and editing of clinical images, investigation results, drawing original diagrams and algorithms, and critical revision for important intellectual content: PSR, DV, GP and RV. The following authors gave final approval of the manuscript: PSR, DV, GP and RV.

**Funding** The authors have not declared a specific grant for this research from any funding agency in the public, commercial or not-for-profit sectors.

**Competing interests** None declared.

**Patient consent for publication** Consent obtained directly from patient(s).

**Provenance and peer review** Not commissioned; externally peer reviewed.

**Open access** This is an open access article distributed in accordance with the Creative Commons Attribution Non Commercial (CC BY-NC 4.0) license, which permits others to distribute, remix, adapt, build upon this work non-commercially, and license their derivative works on different terms, provided the original work is properly cited and the use is non-commercial. See: <http://creativecommons.org/licenses/by-nc/4.0/>.

Case reports provide a valuable learning resource for the scientific community and can indicate areas of interest for future research. They should not be used in isolation to guide treatment choices or public health policy.

## REFERENCES

- 1 Keedy A. An overview of intracranial aneurysms. *MJM* 2006;9:141–6.
- 2 Rinkel GJ, Djibuti M, Algra A, *et al.* Prevalence and risk of rupture of intracranial aneurysms. *Stroke* 1998;29:251–6.
- 3 Findlay JM, Deagle GM. Causes of morbidity and mortality following intracranial aneurysm rupture. *Can J Neurol Sci* 1998;25:209–15.
- 4 Moyle H, Patel AB. Intracranial aneurysms: endovascular treatment. *Mt Sinai J Med* 2010;77:279–85.
- 5 Briganti F, Leone G, Marseglia M, *et al.* Endovascular treatment of cerebral aneurysms using flow-diverter devices: a systematic review. *Neuroradiol J* 2015;28:365–75.
- 6 Porwal MH, Kumar D, Thalner S, *et al.* Analysis of reported adverse events of pipeline stents for intracranial aneurysms using the FDA MAUDE database. *J Cerebrovasc Endovasc Neurosurg* 2023;25:275–87.
- 7 Kallmes DF, Hanel R, Lopes D, *et al.* International retrospective study of the pipeline embolization device: a multicenter aneurysm treatment study. *AJNR Am J Neuroradiol* 2015;36:108–15.
- 8 Becske T, Kallmes DF, Saatci I, *et al.* Pipeline for uncoilable or failed aneurysms: results from a multicenter clinical trial. *Radiology* 2013;267:858–68.
- 9 Delgado A, Kayan Y, Scholz J, *et al.* E-064 institutional experience with Axiom prime extra soft coil for treatment of intracranial aneurysms. *J of Neurointerv Surg* 2017;9:A73–4.
- 10 Ihn YK, Shin SH, Baik SK, *et al.* Complications of endovascular treatment for intracranial aneurysms: management and prevention. *Interv Neuroradiol* 2018;24:237–45.
- 11 Zhao J, Lin H, Summers R, *et al.* Current treatment strategies for intracranial aneurysms: an overview. *Angiology* 2018;69:17–30.

Copyright 2023 BMJ Publishing Group. All rights reserved. For permission to reuse any of this content visit <https://www.bmj.com/company/products-services/rights-and-licensing/permissions/>  
BMJ Case Report Fellows may re-use this article for personal use and teaching without any further permission.

Become a Fellow of BMJ Case Reports today and you can:

- ▶ Submit as many cases as you like
- ▶ Enjoy fast sympathetic peer review and rapid publication of accepted articles
- ▶ Access all the published articles
- ▶ Re-use any of the published material for personal use and teaching without further permission

**Customer Service**

If you have any further queries about your subscription, please contact our customer services team on +44 (0) 207111 1105 or via email at [support@bmj.com](mailto:support@bmj.com).

Visit [casereports.bmj.com](http://casereports.bmj.com) for more articles like this and to become a Fellow