

Dupuytren's Contracture

Carl S. Saiphoo '62

Baron Guillaume Dupuytren was one of the most distinguished of the renowned school of French surgeons who were practising in Paris at the beginning of the nineteenth century. Although the contracture which bears his name was first described by Plater in 1614 and reported in 1823 by Sir Astley Cooper, Dupuytren's dissection and careful description were so definite and precise that his work is considered classical and the condition has since been known as "Dupuytren's Contracture".

Definition:

Dupuytren's contracture, as originally described, is a condition involving the pal-

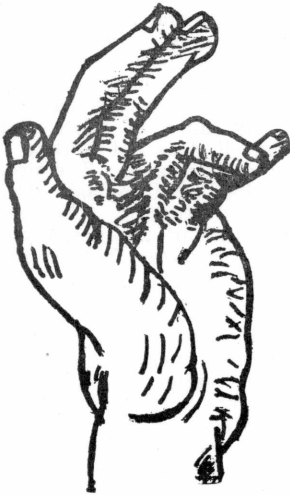

Fig. 1

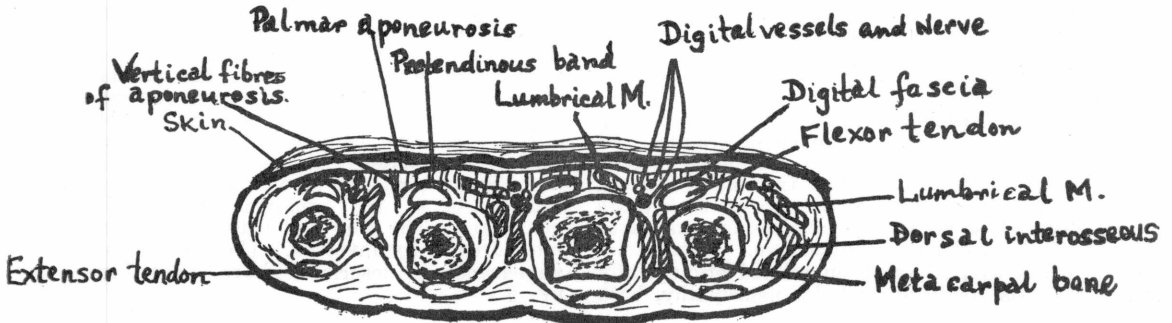
Typical Dupuytren's contracture, with flexion of varying degrees of the ring, little, and middle fingers.

mar aponeurosis and its prolongations and connections, leading to the formation of hard fibrous nodules and bands in the palm, interdigital clefts and digits, and producing contractures of the skin and fingers. (See Figure 1.)

Anatomy and Physiology:

The normal palmar aponeurosis consists of a thin sheet of tissue which lines the palm, lying between the skin and the flexor tendons. The digital nerves and vessels are also beneath it. It is attached proximally to the transverse carpal ligament, possibly as a prolongation of the palmaris longus muscle, (although there is no real agreement on this point) and from here fans out distally across the palm. As it approaches the fingers it collects into four well marked bands, the pretendinous bands, which are linked to each other by finer transverse fasciculi. Just distal to the metacarpophalangeal joints the aponeurosis thins out, and a band passes down the flexor surface of each finger becoming continuous with the digital fascia which envelops the finger as a sheet and contains, within two layers of it, the digital nerves and vessels. When involved, it is this layer which draws the nerves and vessels out of their course, often to the opposite side of the finger. This fact is of great importance when the aponeurosis is being dissected out. These bands end over the middle phalanges of the fingers. None reaches the terminal phalanges. The bands are attached to the fibrous layers of the flexor tunnels and to the sides of the phalanges. (See Figure 2).

The chief function of the aponeurosis is to strengthen the skin of the palm and fingers against the wear and tear of holding and grasping. It also serves to preserve the concavity of the palm by preventing its soft tissues from rising like a ball



when the fist is closed. Its attachments are designed to these ends. It is attached to the skin, to which it is subjacent, by innumerable small strands, while its under surface is tethered to the metacarpal bones by longitudinally directed septa. There is no attachment to the flexor tendons or their sheaths in the palm since these have to move freely beneath it.

The digital aponeurosis is little in evidence in the normal state. However, when it is involved in disease certain areas become thickened and appear as nodular masses on the volar surface or as lateral bands. In Dupuytren's contracture the fibrous tissue which forms in the aponeurosis tends to grow out along its attachments. Extensions may therefore be found in the skin at any point over-lying the aponeurosis, or passing down from its under-surface to the metacarpal bones or sometimes along the lumbrical canals. It is of great importance that the surgeon be acquainted with the details of these attachments if recurrences are to be avoided after operation.

Incidence and Etiology:

Skoog collected 2,278 cases from the literature and reported the following analysis:

Location	No.	Percent
Right hand	663	29%
Left hand	346	16%
Both hands	1,251	55%
Little finger	1,217	53%
Ring finger	1,451	64%
Middle finger	536	24%
Index finger	123	5%
Thumb	73	3%

Male: female ratio—Approximately 8:1.

From these figures it can be seen that the contracture is commoner in the right hand than in the left, and is more commonly bilateral than unilateral. The ulnar side of the hand is most often affected, especially the ring and little fingers.

Bunnell estimates that Dupuytren's contracture occurs in, roughly, 1 to 2 per cent of the general population, and more frequently in the older age groups and in an approximate 8:1, male: female ratio.

Dupuytren himself thought that the disease was caused by repeated trauma, but recently many authors, including Moorhead, have stated that trauma is not an important factor. The majority of authors agree that heredity is involved in some cases of Dupuytren's Contracture. Other diseases which have been related etiologically to this condition include: neuropathy, both

peripheral and central; disorders of the sympathetic nervous system; neurosyphilis; gout; rheumatism; disorders of the endocrine system, such as diabetes, deficiencies of the thyroid and pituitary glands; tuberculosis; various chronic intoxications; local infections; epilepsy; and coronary artery disease. So, we may conclude that the etiology of Dupuytren's contracture is unknown.

Pathogenesis:

Of all the theories, that of Larsen and Posch seems most accurate. They described the pathologic changes as follows: there is an active proliferation of young fibroblasts in intimate association with numerous thick-walled vessels as well as an increasing capillary vascularity. Proliferating tissue forms non-encapsulated nodules of varying size within the aponeurosis. Perivascular inflammation of vessels in the fatty and interstitial tissue around the aponeurosis occurs frequently. These nodules of tissue gradually undergo all of the well-known changes from young, cellular immature fibrous tissue into mature, contracted dense collagenous tissue. As the maturation progresses, the vascularity decreases. The cause of these changes is unknown, but it does not appear to be inflammation or neoplasia. The process can be best described as fibroplasia or fibromatosis of unknown etiology. The significance of iron-pigment in the actively proliferating nodules requires further investigation.

Gross Pathology:

The pretendinous bands of the palmar aponeurosis are thickened and shortened. Often, in the region over the metacarpophalangeal joints, thick nodules, 1-2 cm. in diameter, are seen in the bands. As these bands shorten they pull the overlying skin into folds and dimples and in many areas the skin is intimately attached to the thickened palmar aponeurosis. At times the skin is so firmly bound to the fascia that the two cannot be separated except by creating an artificial dissection plane with a scalpel. The nodules vary from gray-white to white-yellow as the nodule becomes older. Usually the distal palmar and digital fascia are more involved than that in the proximal portion of the hand. The vertical septa which pass from the palmar aponeurosis to the deep or pre-osseous fascia may be involved and tendons, vessels and nerves may be surrounded or angulated by the masses of tissue. In the fingers the disease tends to involve only the digital fascia of the proximal and middle phalanges. The ring and little fingers are most frequently involved. The microscopic appearance is described above. (See Figure 3.)

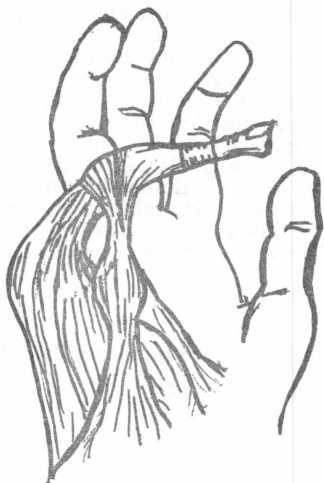


Fig. 3. Gross Pathology of Dupuytren's contracture (Little finger).

The condition usually starts as a firm tender band, palpable beneath the skin of the palm in the line of the fourth or fifth metacarpal bone. The condition may start as an isolated nodule, in which case a longitudinally directed thickening soon appears. The process then spreads down one or more fingers, flexing the knuckle and the proximal (but not the distal) interphalangeal joints. The fourth and fifth fingers are most commonly involved. Extension of the affected fingers is restricted and the limitation is progressive, until its function is crippled. Within the limitations imposed by the contracture, the flexor and extensor tendons are working normally, being uninvolved in the process. Serious secondary damage ultimately occurs in the affected joints. The bones become subluxated and the exposed cartilaginous heads undergo arthritic changes, whilst the joint capsules become grossly contracted on their flexor aspects.

Differential Diagnosis:

(1) **Volkman's contracture**—This condition results from the replacement of the bellies of the long flexor muscles with fibrous tissue. It usually occurs after tight splinting with the elbow flexed following a fracture. The fibrous tissue in the muscles contracts, shortening and tightening the tendons, and so flexing the fingers. All the joints of the fingers are flexed since the flexor tendons extend to the terminal phalanges. In Dupuytren's contracture the terminal joints are unaffected. If the pull is sufficiently strong the wrist may also be drawn up. The fingers cannot be pulled straight unless the tendons are relaxed by flexing the wrist. As the

wrist is extended again the fingers assume their flexed position.

(2) Ulnar Nerve Palsy:

In ulnar nerve lesions the skin of the affected palm fingers is smooth, shiny, soft and atrophic. The hypothenar eminence and the fingers are wasted. The hard masses of subcutaneous tissue characteristic of Dupuytren's contracture are absent. Loss of sensation over the fifth and ulnar half of the fourth fingers, and the inability to use the interossei to adduct and abduct the fingers indicates ulnar nerve palsy.

(3) Congenital Crooked Finger

This condition is usually bilateral and symmetrical. It is confined to the little fingers, which are prevented from full extension by congenital underdevelopment of all tissues on their flexor aspects, including the skin. The metacarpo-phalangeal joints are little if at all involved. The skin and subcutaneous tissues of the flexor aspects are normal in texture but tight. There is neither the thickening of the deep tissues nor the corrugation of the skin found in Dupuytren's contracture, and the sensory loss characteristic of ulnar nerve palsy is absent.

Treatment:

Non-operative—The weight of responsible opinion now holds that conservative treatment with local injections of fat solutions, pepsin, fibrinolysin, copper sulphate and pancreatic extract are all without value. Cortisone and oral vitamin E have also been found to have little or no favourable effect on the disease. Radiation therapy has also been used in the treatment of Dupuytren's contracture. Finney treated 25 patients with radium, fifteen of whom showed good functional results within six months. Exercise of the affected fingers in nearly all cases has also been used but this alone has often caused trauma and more rapid contracture. In some cases a slight improvement was noticed.

Surgical Treatment:

The majority of those experienced in the care of this condition agree that the most successful treatment is surgical, success implying the restoration of a full range of painless movements and freedom from recurrence. This is usually (80-90%) achieved by complete extirpation of the palmar aponeurosis and its extensions, meticulous care in dissection of the hand, and untiring attention to all the details of post-operative rehabilitation. Fasciotomy, or simple division of the contracted bands, and partial fasciotomy, or excision of the diseased fascia with varying margins of uninvolved fascia, are two other operations which are done in selected cases.

Surgery is by no means indicated in all cases of Dupuytren's contracture. There is no doubt that many patients with established contractures of moderate to severe degree require surgical relief and this is especially true when the contracture interferes with the patients ability to carry on with his occupation. When to operate and whether or not to operate on a patient with the earlier stages of the disease pose more difficult problems. One would not likely operate on a patient with contracture if it were reasonably certain that the dis-

ease would remain stationary at that point. On the other hand the operation is technically easier and the results are better when the contracture is in a relatively early stage. When the contracture has existed for so long that there are permanent joint changes, a perfect result is difficult to obtain. Finally, factors which must be considered in determining the type of operation include age, general physical condition, associated diseases, occupation, stage of the disease, and the type of hand.

References:

Bunnell, S.: Surgery of the Hand. Edition 3, p. 229 and 239, J. B. Lippincott Co., 1956.

Christopher's Textbook of Surgery: Edition 7, W. B. Saunders Co., 1960.

Dupuytren, G.: Lancet, 11: 222, 1834.

Finney, R.: Brit. J. Radiol., 28:610, 1955.

Larsen, R. D. and Posch, J. L.: J. Bone and Joint Surg. 40-A: 773, 1958.

Matthews, D. N.: Practitioner, 169: 641, 1952.

Moorhead, J. J.: Ant. J. Surg. 85: 352, 1953.

Skoog, L.: Acta. Chir. Scand., 96: Suppl. 139, 1948.

Smith, N.: Lancet, 1: 565, 1884.

Thomson, G. R.: Brit. Med. J., 11: 1382, 1949.

**Service to the Dental Profession
IN THE MARITIME PROVINCES**



**MARITIME DENTAL SUPPLY CO.
LIMITED**

Halifax, N. S.

St. John, N. B.

**HOW MUCH
WILL YOU HAVE
TO RETIRE ON?**

If it's not very much,
better see a

SUN LIFE
man soon.

F. R. C. MacDONALD